

## Pediatric Aortic Coarctation

Anushi Singh<sup>1</sup>, Poonam Paul<sup>2</sup>

<sup>1</sup>Associate Professor, Child Health Nursing, SNSR, Sharda University, Greater Noida (U.P)

<sup>2</sup>Assistant Professor, Medical Surgical Nursing, Government Nursing College, Gandhinagar (Jammu)

**\*Corresponding Author**

**Email ID: anushi.singh@sharda.ac.in**

### ABSTRACT

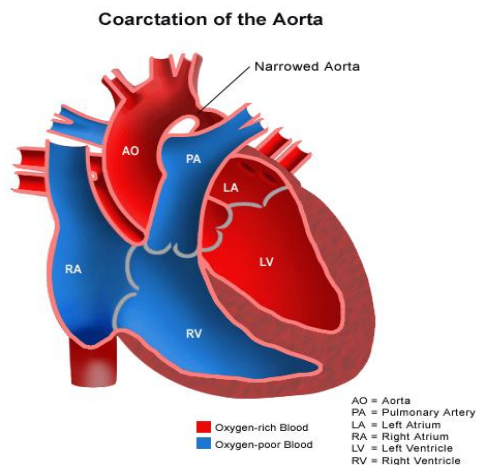
Coarctation of the aorta (CoA) is somewhat common blemish that accounts for 5-8% of all congenital heart defects. Coarctation of the aorta may occur as an isolated deficiency or in association with several other lesions, most usually bicuspid aortic valve and ventricular septal defect (VSD). The finding of coarctation of the aorta may be missed if not an index of suspicion is maintained, and diagnosis is often postponed until the patient develops congestive heart failure (CHF), which is frequent in infants, or hypertension, which is common in older children. This paper discusses the pathophysiology, noninvasive and invasive evaluation, clinical features, and therapy in paediatric patients with coarctation of the aorta.

**Keywords** - Coarctation of the aorta, ventricular septal defect, congestive heart failure.

### DEFINITION OF AORTIC COARCTATION

Coarctation of the aorta is a congenital (present at birth) heart defect involving a narrowing of the aorta, the main blood vessel carrying oxygen-rich blood from the left ventricle of the heart to all of the organs of the body. Coarctation occurs most

frequently in a short segment of the aorta just beyond where the arteries to the head and arms take off, as the aorta arches inferiorly toward the chest and abdomen. This portion of the aorta is called the "juxtaductal" aorta, or the part near where the ductus arteriosus attaches. It is also called the aortic isthmus.



### Incidence of Coarctation of the Aorta

About one-third of children with coarctation of the aorta also have a bicuspid aortic valve—a valve that has two leaflets instead of the usual three. Coarctation of the aorta occurs in a small percentage of children with congenital heart disease. Boys have the defect twice as often as girls do.

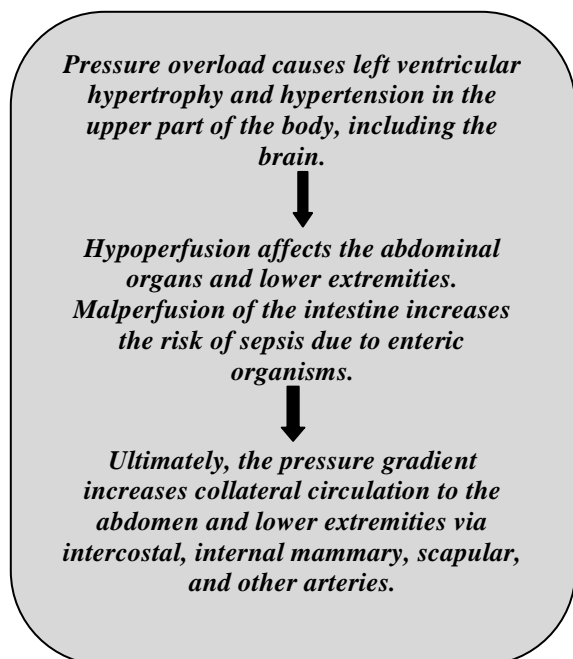
### Pathophysiology of Coarctation of the Aorta

Coarctation of the aorta usually occurs at the proximal thoracic aorta just beyond the

left sub-clavian artery and just across from the opening of the ductus arteriosus. Coarctation rarely involves the abdominal aorta. Thus, in utero and before the patent ductus arteriosus (PDA) closes, much of the cardiac output bypasses the coarctation via the PDA. Coarctation may occur alone or with various other congenital anomalies (eg, bicuspid aortic valve, ventricular septal defect, aortic stenosis, patent ductus arteriosus, mitral valve disorders, intracerebral aneurysms).

### Physiologic Consequences involve Two Phenomena:

- Pressure overload in the arterial circulation proximal to the coarctation
- Hypoperfusion distal to the coarctation.



Untreated coarctation may result in left ventricular hypertrophy, heart failure, collateral vessel formation, bacterial endocarditis, intracranial hemorrhage, hypertensive encephalopathy, and hypertensive cardiovascular disease during adulthood.

### Causes of Coarctation of Aorta

Some congenital heart defects may have a genetic link, either occurring due to a defect in a gene, a chromosome abnormality, or environmental exposure, causing heart problems to occur more often in certain families. Most of the time, this heart defect occurs sporadically (by chance), with no clear reason for its development.

### Symptoms of Coarctation of Aorta

Symptoms noted in early infancy are caused by moderate to severe aortic narrowing. The following are the most common symptoms of coarctation of the aorta. However, each child may experience symptoms differently. Symptoms may include:

1. Irritability
2. Pale skin
3. Sweating
4. Heavy and/or rapid breathing
5. Poor feeding
6. Poor weight gain
7. Cold feet and/or legs
8. Diminished or absent pulses in the feet
9. Blood pressure in the arms significantly greater than the blood pressure in the legs

Mild narrowing may not cause symptoms at all. Often, a school-aged child or adolescent is simply noted to have high blood pressure or a heart murmur on a physical examination. Some may complain of headaches or cramps in the lower sections of the body.

*Note: The symptoms of coarctation of the aorta may resemble other medical conditions or heart problems.*

### Clinical Features of Coarctation of the Aorta

Most often, the coarctation is identified because of a murmur or hypertension detected on routine examination. It is

recommended that palpation of femoral pulses and measurement blood pressure be undertaken during routine examination to avoid delay in the diagnosis. Palpation of the brachial and femoral artery pulses simultaneously will reveal decreased and delayed or absent femoral pulses. Blood pressure in both arms and one leg must be determined; a pressure difference of more than 20 mm Hg in favor of the arms may be considered evidence for AC. The LV impulse may be increased. A thrill is usually felt in the suprasternal notch. The first and second heart sounds are usually normal in isolated aortic coarctation. Because of the large percentage (up to 60%) of patients with AC have associated bicuspid aortic valve, an ejection systolic click may be heard at the apex and left mid and right upper sternal borders; this click is constant and does not change with respiration. An ejection systolic murmur may be heard best at the left or right upper sternal borders, but is usually heard best over the back in the left interscapular region. Sometimes, a faint continuous murmur may be heard in the left interscapular region, secondary to continuous flow in the coarcted segment or on the back (secondary to flow in the collateral vessels).

#### NON-INVASIVE ASSESSMENT

**Chest Radiograph:** Chest roentgenogram may show significant cardiomegaly or the heart size may be normal. Rib-notching secondary to collateral vessels may also be seen. Other roentgenographic features include a “3” sign on a highly penetrated chest radiograph (frontal view) or inverted “3” sign of the barium-filled esophagus.

#### Electrocardiogram:

The electrocardiogram may be normal or it may show LVH. Sometimes the LVH may be manifested by increased S waves in leads V5 and V6, the so-called posterobasal LVH.

#### Echocardiography-Doppler Studies:

Echocardiographic imaging usually reveals the coarctation in suprasternal notch, two-dimensional echocardiographic views. Increased Doppler flow velocity in the descending aorta by continuous wave Doppler and a demonstrable jump in velocity at the coarcted segment by pulsed-Doppler technique are usually present.

Instantaneous peak pressure gradients across the AC can be calculated by employing a modified Bernoulli equation:

$$\Delta P = 4 V_2^2 - V_1^2 = ( )$$

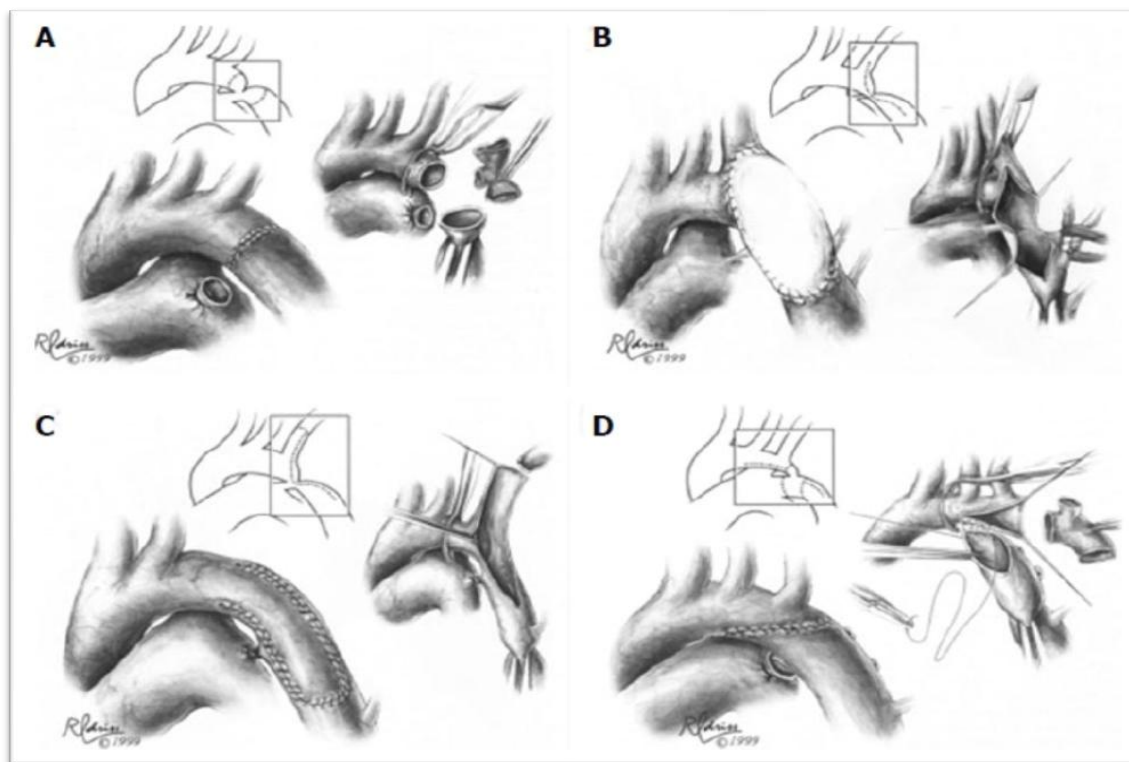
where – P is peak instantaneous gradient and V2 and V1 are peak flow velocities in the descending aorta distal to coarctation (continuous-wave Doppler) and proximal to the coarctation (pulsed Doppler), respectively.

**MRI/MR Angiography:** These studies are useful in demonstrating the anatomy clearly. If the clinical and noninvasive evaluation outlined above indicates the need for intervention.

#### TREATMENT OF COARCTATION OF THE AORTA

- In a critically ill newborn, the goals of management are to improve ventricular function and restore blood flow to the lower body. A nonstop intravenous medication, prostaglandin (PGE-1), is used to open the ductus arteriosus (and maintain it in an open state) allowing blood flow to the body beyond the coarctation. It is also often needed to begin intravenous medications that improve the contraction of the heart muscle. Babies will almost always need to be placed on a ventilator before surgery.

- In symptomatic newborns with coarctation, surgical repair is usually done on an urgent basis following initial stabilization. Rarely, an infant will not improve with medical therapy and surgery must proceed before the infant has been stabilized.
- There a number of surgical techniques to repair coarctation. A common repair involves resection (removal) of the narrowed area with anastomosis (reconnection) of the two ends to each other. This repair is called an end-to-end anastomosis. Another common repair involves taking the aorta after the area of narrowing and anastomosing it with the ascending aorta. This type of repair is called an arch advancement and is done when there is more diffuse hypoplasia. Less commonly, the narrowing may be opened with a patch, or a portion of an artery may be used as a flap to expand the area (called a subclavian flap aortoplasty).
- **Choice of surgical technique** depends on anatomy and center preference. Surgical mortality rate is < 5% for symptomatic infants and < 1% for older children. Rarely, paraplegia results from cross-clamping of the aorta during surgery. Balloon angioplasty is highly effective in treating recurrent coarctation after surgery.



### Patient Follow Up

Patients with repaired or unrepaired coarctation must be followed by a cardiologist throughout their lifetime. For those who have undergone repair, this follow-up should be at least annually, with

specific attention paid to baseline or exercise-induced hypertension.

### REFERENCES

1. Anderson RH, Lenox CC, Zuberbuhler JR. Morphology of ventricular septal

- defect associated with coarctation of aorta. *Br Heart J.* 1983;50:176–181.
- Rosenthal E. Coarctation of the aorta from fetus to adult: curable condition or lifelong disease process? *Heart.* 2005;91:1495–1502
  - Liberman RF, Getz KD, Lin AE, Higgins CA, Sekhavat S, Markenson GR, Anderka M. Delayed diagnosis of critical congenital heart defects: trends and associated factors. *Pediatrics.* 2014;134:e373–e381
  - McBride KL, Zender GA, Fitzgerald-Butt SM, Koehler D, Menesses-Diaz A, Fernbach S, Lee K, Towbin JA, Leal S, Belmont JW. Linkage analysis of left ventricular outflow tract malformations (aortic valve stenosis, coarctation of the aorta, and hypoplastic left heart syndrome) *Eur J Hum Genet.* 2009;17:811–819.
  - Kappetein AP, Zwinderman AH, Bogers AJ, Rohmer J, Huysmans HA. More than thirty-five years of coarctation repair. An unexpected high relapse rate. *J Thorac Cardiovasc Surg.* 1994;107:87–95.
  - Yetman AT, Nykanen D, McCrindle BW, Sunnegardh J, Adatia I, Freedom RM, Benson L. Balloon angioplasty of recurrent coarctation: a 12-year review. *J Am Coll Cardiol.* 1997;30:811–816.