

Ayurvedic Management of Glaucoma Progression: A Case Study

Patil Ashwini A^{1*}, Dakhore Jyoti R², Thorat Kavita R³, Chitrakar Mrudul Y⁴

¹ Professor Department of Shalakyatantra Dr. D. Y. Patil School of Ayurved, Nerul, Navi Mumbai, Maharashtra

² Associate Professor, Department of Shalakyatantra Vidarbha Ayurved Mahavidyalaya, Amravati Maharashtra

³ Associate Professor, Department of Shalakyatantra Dr. D. Y. Patil School of Ayurved, Nerul, Navi Mumbai, Maharashtra

⁴ Associate Professor, Department of Swasthavritta Dr. D. Y. Patil School of Ayurved, Nerul, Navi Mumbai, Maharashtra

***Corresponding Author**

Email Id: drashwinipatil14@gmail.com

ABSTRACT

Glaucoma is a group of eye disorders that lead to a progressive damage to the optic nerve. People with glaucoma can lose nerve tissue resulting in vision loss. The most common form of glaucoma, primary open-angle glaucoma, develops slowly and usually without any symptoms. Glaucoma is a disease that initially affects peripheral (side) vision. Often, it is difficult to recognize that peripheral vision is changing during normal daily activities because the deficits can be subtle and one eye can compensate for the other. If left untreated, glaucoma can lead to significant vision loss in both eyes, and may even lead to blindness. One of the key tests for diagnosing glaucoma is the visual field test, which is repeated periodically to determine if the disease is stable or getting worse. A 47 years female patient came to OPD with c/o eye strain and diminished vision. K/C- POAG since 2 years on Latanoprost eye drop. Local Examination- Ant. Seg- N, Vn 6/60 BE, IOP of LE was still raised hence advised perimetry which shows severe visual field defects. Taking into consideration samprapti of the disease, patient was treated with GokshuradiGuggul and ChandraprabhaGutika for 16 wks. Significant relief was observed in signs, symptoms, IOP came to normal range and Perimetry showed significant improvement in visual field defect.

Keywords: *Perimetry, Visual field Defects, Glaucoma, Gokshuradiguggul, Chandraprabhagutika, IOP. Primary Open Angle Glaucoma.*

INTRODUCTION

Glaucoma is a disease that initially affects peripheral (side) vision. Often, it is difficult to recognize that peripheral vision is changing during normal daily activities because the deficits can be subtle and one eye can compensate for the other [1]. There are approximately 11.2 million persons aged 40 years and older with glaucoma in India. Primary open angle glaucoma is estimated to affect 6.48 million persons [2]. The estimated number with primary angle-closure glaucoma is

2.54 million. Those with any form of primary angle-closure disease could comprise 27.6 million persons [3]. Most of those with disease are undetected and there exist major challenges in detecting and treating those with disease. One of the key tests for diagnosing glaucoma is the visual field test, is repeated periodically to determine if the disease is stable or getting worse [4]. As the disease progresses, more and more of the peripheral vision is lost until eventually, in very late and advanced disease, the central vision is also affected.

Sometimes there are patients with glaucoma who have their central vision affected early in the course of the disease, which is another reason that formal visual field testing is so important [5].

AIMS AND OBJECTIVES

- 1) To assess the effect of *Gokshuradi guggul* on I.O.P.
- 2) To assess the effect of *Gokshuradi guggul* and *Chandraprabha gutika* on Visual Field Defects in Primary Open Angle Glaucoma

MATERIALS AND METHODS

Case Study

Patient's Name: ABC

Age: 47 years.

Sex: female

Came to OPD with Complaints:

- 1) Eye strain since 2 years
- 2) Diminished vision since 2 years
- 3) K/C: Primary Open Angle Glaucoma since 2 yrs on local medication Latanoprost Eye Drops BD
- 4) Local Examination reveals -Ant. Seg.- N Both Eyes

Signs & Symptoms	Before Treatment	
	RT EYE	LT EYE
Vn	6/60	6/60
Vn with glass	6/9	6/12
IOP in mm of Hg	17.3	31.6

Intra Ocular Pressure (IOP) of Left Eye was still raised hence advised perimetry. Perimetry reports showed severe visual field defects. Date 13/03/2015

Before Treatment		RT EYE	LT EYE
Visual Field Defects	MD	-16.08 dB	-12.17 dB
	PSD	17.63 dB	15.85 dB
Funduscopy	CDR	0.6	0.8

Written informed consent was taken. Taking into consideration samprapti of the disease, patient was treated with *Gokshuradi Guggul* and *Chandraprabha Gutika*. Goal for the treatment of patient was to control the I.O.P. and restore vision and Visual Field Defects.

Treatment Given [6]

To control the Intra Ocular Pressure:-

- 1) *Gokshuradi Guggul* 3 (250mg/tab) bd for 2 wks followed by 2 bd for 10 wks.
- 2) After 4 wks when IOP was controlled, then treatment for Vision improvement was started with
- 3) *Chandraprabha Gutika* 2 (250mg/tab) bd for 12 wks.
- 4) Follow up was taken for every week for 1st four wks then every 15 days for next 12 wks.

Right Eye Perimetry
Before Treatment 13/03/2015 & After Treatment 5/09/2015

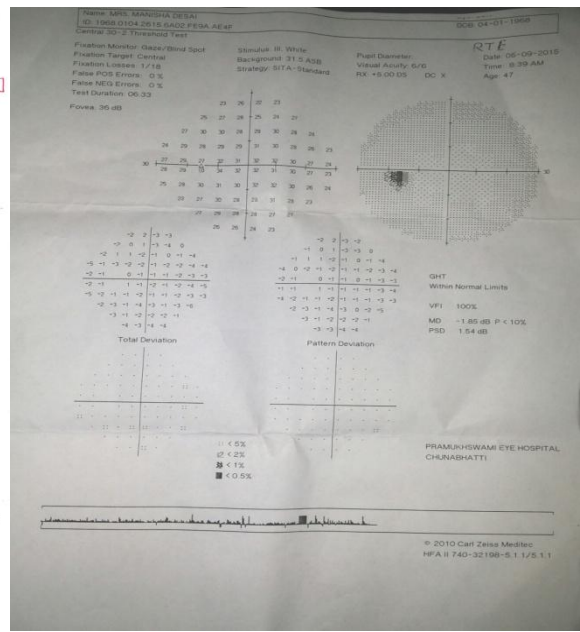
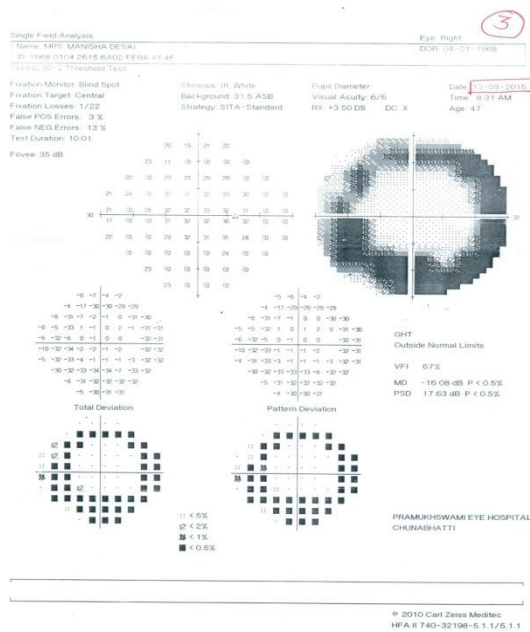


Fig. 1. Right Eye Perimetry

Left Eye Perimetry
Before Treatment 13/03/2015 & After Treatment 5/09/2015

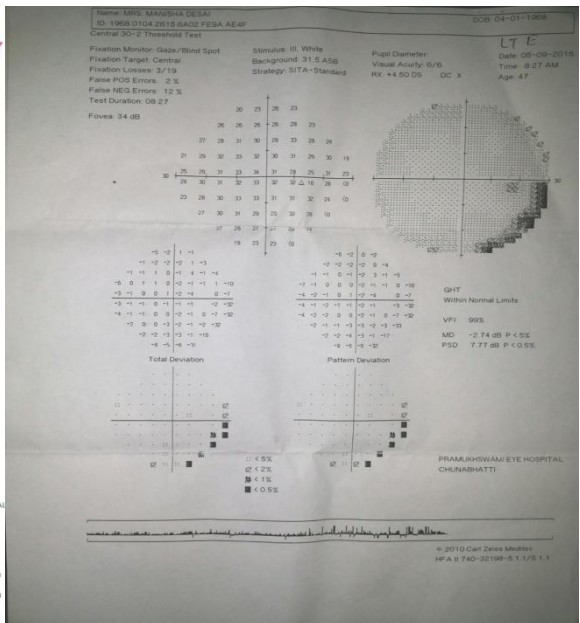
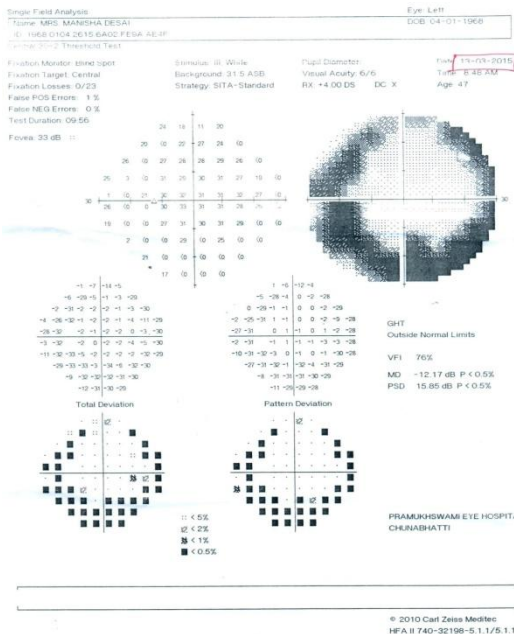


Fig. 2. Left Eye Perimetry

OBSERVATION AND RESULTS

Date		13/03/2015		05/09/2015	
Signs & Symptoms		Before treatment		After treatment	
		RT	LT	RT	LT
Vn		6/60	6/60	6/36	6/36
Vn with glass		6/9	6/12	6/6	6/9
IOP mm of Hg		17.3	31.6	17.3	18.9
Visual field defects	MD	-16.08dB	-12.17dB	-1.85dB	-2.74dB
	PSD	17.63 dB	15.85dB	1.54dB	7.77dB

It was observed that there was improvement in vision with glass and without glass by one line on Snellens chart. After the treatment of 8 weeks IOP came to normal. Perimetry was repeated after 16 weeks of treatment which shows significant reversible changes in visual field defects.

Perimetry showed changes in:

Mean deviation (MD) from -16.08dB to -1.85dB in RT eye and -12.17dB to -2.74dB in LT eye.

(PSD) pattern standard deviation changed from 17.63dB to 1.54dB in RT eye and 15.85dB to 7.77dB in LT eye.

DISCUSSION AND CONCLUSION

Discussion regarding the Pathophysiology of the Disease, its Progression, Glaucoma is a group of Eye Disorders that lead to Progressive Damage to the Optic Nerve [7]. People with Glaucoma can lose nerve tissue, resulting in vision loss. The most common form of glaucoma, primary open-angle glaucoma, develops slowly and usually without any symptoms. Many people are not aware they have the condition until they have significant vision loss [8]. Initially, glaucoma affects peripheral or side vision, but it can advance to central vision loss. If left untreated, glaucoma can lead to significant vision loss in both eyes, and may even lead to blindness. Glaucoma, a leading cause of

irreversible visual loss, is characterized by loss of retinal ganglion cells (RGC) and their axons over a period of many years. Glaucomatous optic neuropathy is characterized by changes in the optic disc and visual field defects mostly because of raised intra-ocular pressure. The morphologic changes in the optic disc are in the form of thinning of neuroretinal rim, pallor and progressive cupping of the optic disc. The hemorrhage-associated retinal nerve fiber layer defects precede measurable changes of the optic disc configuration. The visual field defects in glaucoma are often detected only after 40% of the axons are lost. Glaucoma cannot currently be prevented. But if it is diagnosed and treated early, it can usually be controlled. Medication or surgery can slow or prevent further vision loss.

Mode of Action of Individual Drugs in Detail

Significant changes were observed in vision, IOP, and visual field defects. *Musta*, *Gokshur*, *Haritaki*, *Bibhitaki* are ACE inhibitor so act as hypotensive and ocular hypotensive. *Amalaki*, *Haritaki*, *Bibhitaki* and *Shunthi* are anti-atherosclerotic so reduce sclerosis and increase outflow of aqueous. *Chandraprabha Gutika* is *Chakshushya* thus help to improve vision and visual field defect. It is described in Arshachikit Saadhyay that intake of Chandrapabha Gutika increases the strength of sense organ. Person become strong like

Elephant, speedy like horse, his vision increases like Eagle, hearing capacity like Varah and become intelligent like Brihaspati. So Chandraprabha Gutika is used in this case which helps not only to restore the vision but also help to improve peripheral vision

REFERENCES

- 1) George, Ronnie MS; Ve, Ramesh S. MPhil; Vijaya, Lingam MS. Glaucoma in India: Estimated Burden of Disease. Journal of Glaucoma: August 2010 - Volume 19 - Issue 6 - p 391-397. doi: 10.1097/IJG.0b013e3181c4ac5b
- 2) Current concepts in the pathophysiology of glaucoma. Renu Agarwal, Suresh K Gupta, Puneet Agarwal, Rohit Saxena,¹ and Shyam S Agrawal. Indian J Ophthalmol. 2009 Jul-Aug; 57(4): 257–266
- 3) Young H. Kwon, John H. Fingert, Markus H. Kuehn, and Wallace L.M. Alward. Review article mechanisms of disease free preview. Primary Open-Angle Glaucoma
- 4) <https://www.aoa.org/patients-and-public/eye-and-vision-problems/glossary-of-eye-and-vision-conditions/g>
- 5) <http://www.jahm.in/index.php/JAHM/article/view/18>
- 6) <http://www.evaidyaji.com/Ayurvedic/Ayurvedic%20Herbs/Gokshura>
- 7) <http://dir.indiamart.com/impcat/gokshuradi-guggulu.html>
- 8) Jima Guggul causes moderate degree of diuresis. Bhaishajyaratnavali–Publication–Choukhamba Sanskrit sansthan, Varanasi. Edition – 16th (2002) Arshachikitsa prakaransh loka 228.